

## A SUCCESSFUL ANESTHETIC TECHNIQUE IN A PATIENT WITH A GIANT EMPHYSEMATOUS BULLA

Arif Al-Arieibi, M.D., Timothy J. Maxwell, M.D.

The University of Western Ontario, London, ON, Canada

**Abstract:** This case report describes the successful use of combined regional and general anesthesia in a patient with severe chronic obstructive pulmonary disease (COPD) and a giant emphysematous bulla undergoing open reduction of a proximal humerus fracture. An ultrasound-guided supraclavicular block was placed preoperatively and a double-lumen endotracheal tube (DLETT) with temporary one lung ventilation (OLV) was used to deliver a general anesthetic. Few cases of severe bullous emphysema have been reported but none have used such a technique.<sup>1</sup>

**Clinical features:** A 62-year-old patient with a proximal fracture of the left humerus required an open fixation in the sitting position. The patient had a giant emphysematous bulla in the right lung (Figure 1), resulting in very limited respiratory reserve and CO<sub>2</sub> retention. In addition to the usual anesthetic goals for severe COPD patients, other special considerations in this case were the avoidance of positive pressure ventilation to the right lung, avoidance of high airway pressures during the temporary OLV of the left lung, avoidance of high concentrations and volumes of local anesthetic while managing the supraclavicular block and use of ultrasound-guided regional technique.<sup>2</sup> An ultrasound-guided supraclavicular block was performed preoperatively and the general anesthesia technique included use of a rapid sequence induction and a DLETT. The right lung was isolated immediately after intubation and the left lung was ventilated until spontaneous breathing resumed. Anesthesia was maintained with spontaneous two-lung ventilation throughout the procedure. 17 days later, the patient underwent a similar procedure for a second fracture at the same site. The same regional and general anesthetic techniques were again used successfully.

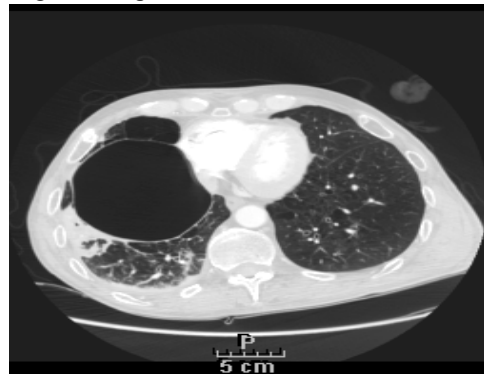


Figure 1: Computerized Tomography scan demonstrating a giant emphysematous bulla in the right lung.

**Conclusion:** In addition to the usual challenges of regional and general anesthetic techniques in severe COPD, additional unique perioperative considerations in this case included the risk of bulla rupture and the controversial use of regional techniques in such patients. Despite controversy surrounding use of regional techniques in this patient population, careful administration of the combined technique was instrumental to the successful outcome of both surgeries.

**References:** 1. Carbonell, J.R. *et al.* (2008) *Rev Esp Anesthesiol Reanim* 55: 253-4.

2. Riazi, S. *et al.* (2008) *British Journal of Anaesthesia*. 101: 549-56.